

An evaluation on the use of adjustable compression wrapping devices as an alternative to compression bandaging in lower leg wounds



Author:
Natalie Lee

An evaluation of the use of an adjustable compression wrap (easywrap[®], Haddenham Healthcare) was conducted within a UK-based wound healing clinic. The aim was to investigate if this adjustable compression wrapping device (ACWD) was a cost-effective alternative to short-stretch, combination short-stretch and long-stretch compression bandage kits for patients with chronic oedema and lower leg wounds. Secondary aims were to consider if concordance was improved with long-term use of the device as part of maintenance therapy, the main outcome measure for this being if there was ulcer recurrence. Five patients with venous leg ulcers, including some which were not healing, were selected and treated with the short-stretch ACWD instead of standard leg ulcer bandaging techniques over an 18-week period and indefinitely as part of ongoing maintenance. From the case studies discussed, all wounds improved with the use of the easywrap ACWD and improved patients' quality of life and concordance with compression therapy. Furthermore, cost savings are demonstrated when using an ACWD instead of standard leg ulcer bandaging after 1 month of treatment.

Compression therapy forms one of the cornerstones of effective leg ulcer treatment, with bandaging being an appropriate treatment modality (SIGN, 2010). Chronic wound and oedema management can put significant pressure on clinicians' time and budget resources, especially when patients require multiple visits per week (Wigg and Lee, 2014). Many patients struggle with standard compression therapy options given associated challenges to hygiene and potential pain levels (Todd, 2011), especially when this therapy needs to continue over an extended period of time or demands increased visits to a clinic.

In order to improve patient quality of life, concordance and involvement, and in an attempt to reduce wound recurrence rates and improve healing rates, alternative methods of compression therapy have been considered in the clinic. While there are wrap garments already available, which are designed for wound care, the wrap garment considered is currently used in lymphoedema and is a short-stretch garment made with overlapping straps, with hook and loop fasteners on one

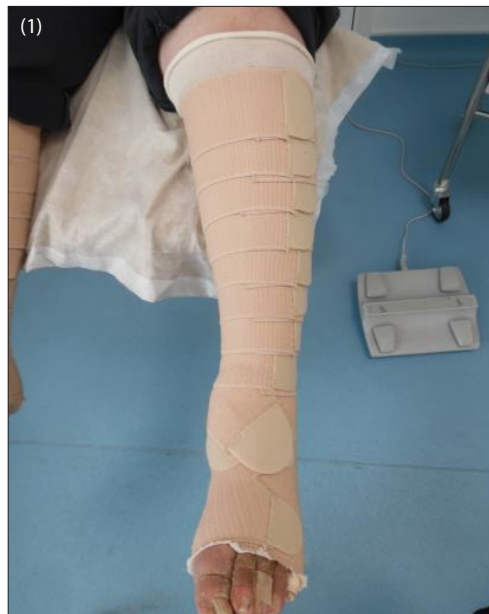side. Easywrap[®] (Haddenham Healthcare) is designed to mimic the standard 50% overlap of a more traditional bandage with a weave that is designed to reduce risk of kinking. Due to its high static stiffness, it aims to be easy to apply, with a consistent graduated compression, without the need for a gauge to check if the correct pressure has been achieved, which was preferred for patient ease and safety of use (*Figures 1 & 2 show easywrap in situ*).

The Burden of leg ulcer costs the NHS somewhere in the region of £400million per year in the UK and is thought to affect in the region of 130,000 people (Ritchie, 2017). However, other estimates set prevalence at between 1–3% of the population (Todd, 2011), which could see incidence as high as 1,950,000 (Lee and Lawrance, 2017). The most common form of leg ulcer is that which is classified as venous in origin, which is thought to affect 60% of all those who experience leg ulcers (Ritchie, 2017).

Venous disease occurs when there is damage to the valves within the veins, which would usually prevent backflow and venous hypertension, when

Natalie Lee is Lymphoedema Clinical Nurse Specialist, Clinical Manager, Haddenham Healthcare Ltd

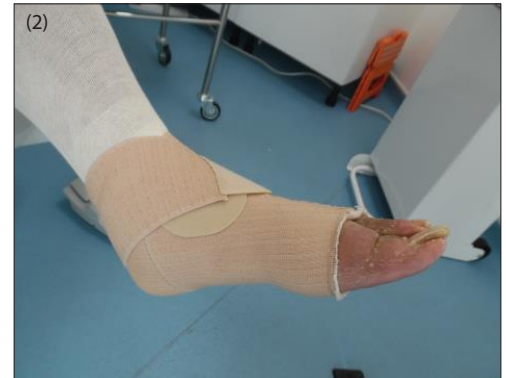Figures 1 and 2. Easywrap in situ.



a patient goes from supine to standing (Nazarako, 2017). This leads to venous insufficiency and due to increased capillary filtration into the tissues, will often predispose the patient to oedema formation (Elwell, 2015). This is due to the impact that venous insufficiency has on the capacity of the lymphatics which, as well as functioning as part of the immune system, has a primary role in the transportation of 100% of interstitial fluid back into the circulatory system (Woodcock and Woodcock, 2012). The lymphatic system becomes overwhelmed and unable to effectively transport the fluid which, if left untreated and present for more than 3 months, will be defined as a chronic oedema (Moffatt et al, 2016).

In the study conducted by Moffatt et al (2016), it was highlighted within one demographic region that 22.5% of inpatients with chronic oedema also had a wound and, of the community patients assessed, 52.6% of those with chronic oedema presented with a wound. When assessing using the CEAP classification [Table 1] (Nazarako, 2017), oedema can present prior to the development of a wound. It is important to recognise that as the venous disease progresses there will be a further impact on the ability of the lymphatic system to cope, hence, oedema will develop.

When classifying the level of venous disease, it is equally important to recognise the link with chronic oedema and classify it in its own right, using the international benchmarks for classification detailed in Table 2 (Lymphoedema Framework, 2006). According to Williams (2017), there are several articles that detail case studies where adjustable compression wraps have been successfully used in venous leg ulcer management. Demonstrating reductions in oedema, improvement in wound



healing, pain and quality of life. Furthermore, cost savings can be demonstrated when using ACWD compared to traditional bandaging techniques, due to reduced frequency of visits and application as they are re-useable (Wounds UK, 2015).

In the treatment of venous leg ulcers, evidence indicates that wound healing is promoted when compression of >40 mmHg is applied (Todd, 2011; Wounds UK, 2015). Furthermore, prevention of recurrence can be achieved by using compression therapy with pressure of up to 35 mmHg (Moffatt, 2007). Previously, a 4-layer bandaging system, which acts to build an appropriate level of compression over the limb has been used in the treatment of venous leg ulcers, however, evidence suggests that these are not well tolerated by patients, especially where oedema is present (Damstra and Partsch, 2013), as they apply a constant resting pressure and lower working pressure. This means that when resting, patients often report discomfort due to the constant pressure of the bandages. This can result in concordance issues and patients removing bandages.

When using an ACWD, these are manufactured to work as a short-stretch bandage would (Williams, 2017), which gives a lower resting pressure and has a higher working pressure when the patient goes from supine to standing (Damstra and Partsch, 2013). This consistent lower resting pressure means that comfort is improved and treatment is better tolerated, even in those patients who have restricted mobility (Elwell, 2015). Furthermore, the use of short-stretch compression systems, such as ACWDs, are seen to have an acceptable level of static stiffness, appropriate for the reduction of oedema (Lee, 2017) and relates to the difference in the pressure of a material on the limb when going from lying to standing, in mmHg divided by 1 (Partsch, 2005). The ability of a compression device to achieve a difference in pressure of greater than 10 mmHg is thought to be more effective at reducing oedema (Damstra and Partsch, 2013). Furthermore, Partsch (2005) states that short-

Table 1. CEAP Classification for venous disorders.

Stage	Symptoms
C0	No visible or palpable signs of venous disease
C1	Telangectasia (spider veins) or reticular veins
C2	Varicose veins, 3mm diameter or more
C3	Oedema
C4	Skin and subcutaneous tissue changes: classified below to distinguish severity
C4a	Pigmentation or eczema
C4b	Lipodermatosclerosis or atrophie blanche
C5	Healed venous ulcer
C6	Active venous ulcer

(Elkof et al, 2014) Taken from Nazarko (2017).

Table 2. ISL Stages of Lymphoedema.

Stage	Symptoms
0	Sub clinical with no evidence of oedema
I	Early onset oedema that reduces with elevation
IIa	Limb elevation does not reduce the swelling: tissues are pitting
IIb	Tissue fibrosis results in non-pitting tissues and persistant swelling
III	Persistent swelling: marked skin and tissue changes

stretch compression systems still have the ability to intermittently occlude the veins and reduce venous hypertension, while maintaining a comfortable and effective resting pressure.

Methods

Five patients presenting with lymphoedema/ lymphovenous changes and a chronic venous leg ulcer of greater than 6-week duration or a chronic wound of alternative origin, such as trauma, that has failed to heal normally due to compromised venous status, were provided with an easywrap ACWD based on leg size, applied instead of traditional bandaging at initial assessment or once the wound exudate was under control. The wrap garments are advised in the local clinic pathway for lymphovenous wounds requiring frequent dressing changes, patients unable to tolerate bandages or where a wound is suspected to take longer than 12 weeks to heal.

Dressing regimens were selected based on clinical appearance of the wound and wound care objectives as per local formulary. All patients received standard compression therapy until their wrap garments arrived, unless a set was available at time of assessment. The donning and doffing was demonstrated by the clinician. Patients were then asked to repeat the procedure until the clinician was satisfied with the application by the patient (or a patient's selected helper). Patients were reviewed at each dressing change and their wounds were measured and evaluated every 4 weeks, or if their

condition changed. The patients were encouraged to wear their wrap system continuously, but were allowed to remove them for hygiene purposes. No demographic patient data, or information relating to the clinic is included in the case studies mentioned and all patient images have been anonymised in line with data protection policies.

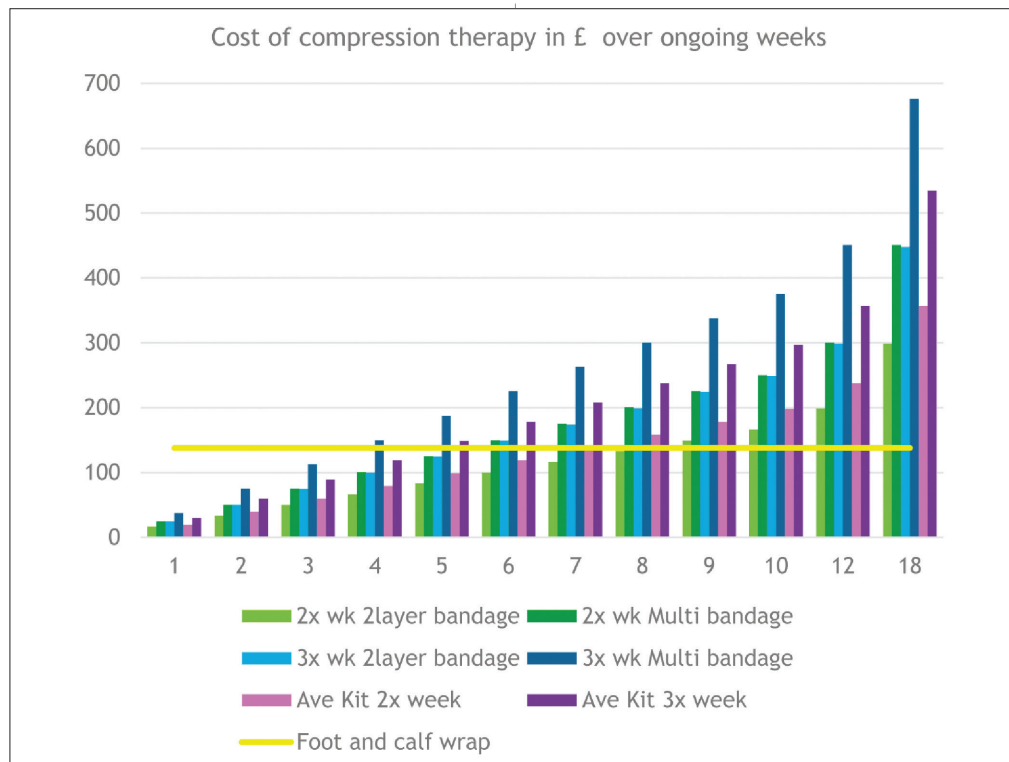
Results

Time efficiency

All patients reviewed gave feedback on how reduced appointment times improved their quality of life in terms of not having to spend so much time in clinic. The ability to remove or adjust the garment if it was uncomfortable enhanced concordance with treatment and enabled each patient to wash easier with the use of a water-resistant dressings or waterproof cast protector as appropriate to their needs.

One patient went from a 1 hour 30 minute appointment to a 45 minute appointment when moving from bilateral wound care and bandaging with combination kit bandages to using the ACWD. As well as time saved in terms of staff training to become proficient in bandaging techniques, time saved came primarily from removal of 'spent' bandages and increased time on skincare, as the patient was now able to perform skin at home. Further time was saved by not having to reshape the leg with padding to accommodate for slippage from standard compression bandaging, which occurred where the oedema had reduced and the

Figure 3. Cost Comparison of Easywrap versus bandages over 18 weeks.



bandages could not accommodate this change. Both the patient and staff felt that their leg shape had improved, which was established by reduced need to reshape the leg with a wool product prior to bandaging/ applying wrap. Less slippage was observed as the wrap stayed at 2 cm below knee, rather than further down the leg. Vertical 'guttering' seen in the limb indicating lymph drainage and skin contracture. A more traditional ankle/calf curve developed, rather than a cylinder or cone-shaped leg as the patient was able to adjust the straps on the wrap garment as often as needed.

The same patient has now reduced to weekly clinical visits and manages self-wound care at home during the rest of the week, which has enabled her return to work. This, in turn, has enabled the 4 hours 15 minutes of clinical time to be reallocated weekly. Her quality of life has significantly improved as the wound is no longer her primary focus; she is able to enjoy activities with her family and was very keen to get back to work.

Cost effectiveness

Initially, the cost of an ACWD seems more expensive than a short-stretch bandage, foam or combination bandage kit. It is clear from *Figure 3* that this cost is met generally within 1 month for kits applied 3 times per week and by 6 weeks when using the 2-layer short stretch bandage system. If the patient is bandaged twice weekly

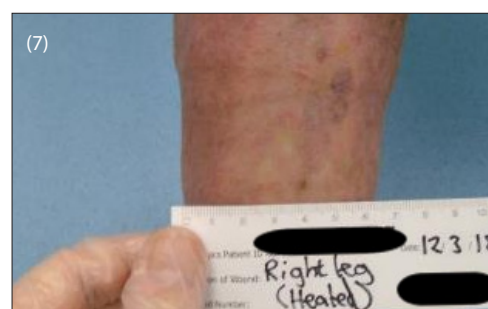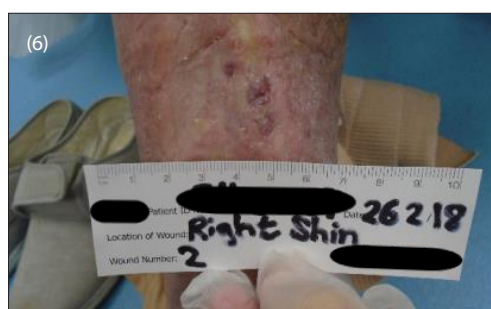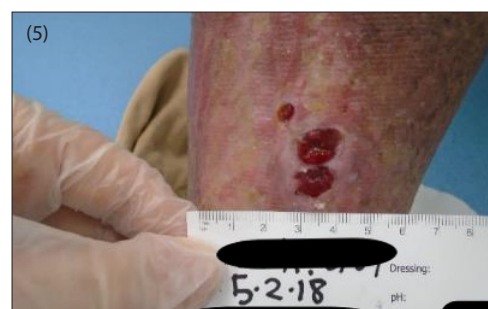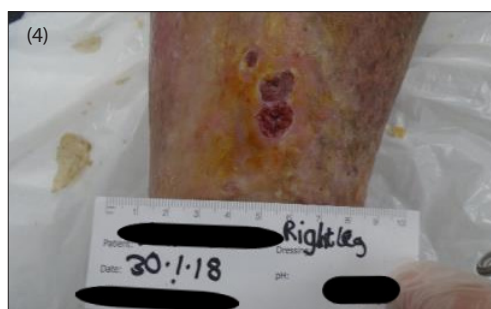only, then an additional 3–4 weeks were needed to match the cost of bandaging. Furthermore, risks associated with bandaging, such as trauma or slippage, were reduced as the ACWD could be adjusted as required.

Additionally, as part of treatment for lymphovenous ulcers, patients should be provided with compression garments to prevent future ulceration. In the cohort of patients already in an ACWD there is no additional cost at the end of the treatment to order such garments, which can range from £20 to over £100 if they require made-to-measure garments; or indeed go on to maintain in a wrap garment should they struggle with more routine circular/flat knit donning and doffing. Anecdotal evidence from practice suggests it is not uncommon to find frequent additional costs in 'maintenance' bandaging while waiting for garments to arrive, which can take several weeks to a month; this has not been accounted for in the cost comparison as the potential choice of garment is too broad and falls outside of the scope of this work.

Skin care

In practice, a common presentation in those with leg ulcers is poor skin integrity/hygiene. This can become exacerbated by compression bandaging/kits if skin care is not performed or not applied frequently enough; it is not uncommon for the surrounding skin integrity to require increased visits compared to the wound.

Figures 4–7 showing improvement in wound and surrounding skin while using easywrap over a 6 week period.



The ACWD allows for the wound to be dressed while the rest of the leg skin to be cleansed and moisturised daily, significantly improving the surrounding skin integrity.

Case study 1

In case study one, the surrounding tissue improved in a short space of time with a combination of skin care at appointments and daily moisturising with ointment-based emollients.

The surrounding hyperkeratosis has desquamated and, over the course of the treatment, appears less fibrosed, reducing the risk of ulcer recurrence or infection. This wound had compression therapy applied solely by using the ACWD; within 1 month, the wounds had epithelialised, within 6 weeks they were fully intact. The patient was discharged in March 2018 as managing well with his own skin care and use of wrap as long-term maintenance.

The improvement in skin was a consistent finding throughout all patients using the garment, but was particularly significant in this case as his skin was in poor state due to the length of time he had been in bandaging even with an emollient being applied at each appointment.

Figures 4–7 show the wound healing progress from case study one.

Flexibility

Anecdotal evidence from practice highlights that many patients find compression bandaging uncomfortable or struggle to keep up with hygiene, especially if they have bilateral wounds or a higher body mass index. Where a patient has high levels of wound pain, it is a challenge for both

patient and clinician to agree on a plan of care that is comfortable, while remaining therapeutic.

Case study 2

The patient who could not tolerate any form of compression therapy prior to her referral to the service. Whenever a bandage or kit was applied she was only able to tolerate for up to 24 hours before removing, she would often try to reapply the compression herself, increasing the risk of bandage-related injury. The patient had developed a wound in April 2017 and attended the clinic in November 2017 after managing primarily at home with occasional check-ups with the practice nurse to enable dressings to be ordered. During her assessment, the use of an ACWD was suggested, at which the patient was enthusiastic. While the patient did not wear the ACWD consistently, she was able to don and doff as required in response to her level of pain; there was no additional cost for this removal and reapplication of compression as she was able to do this at home without a nurse present. This plan of care enabled the turning point to achieve slow, but visible, healing in this 8-month-old ulcer.

On assessment after 3 months of using the ACWD, the necrosis lifted [Figures 8 and 9] and malodour significantly reduced, improving her quality of life and alleviating her anxiety. Three months into treatment the patient is still only able to tolerate compression intermittently, but the wound continues to heal slowly, there are growing formations of epithelial islands in the medial aspect of the wound, which the clinical team and patient are hopeful will continue to proliferate.

Figure 8 (left) and Figure 9 (right) show improvement in the wound bed following 12 weeks of using easywrap.

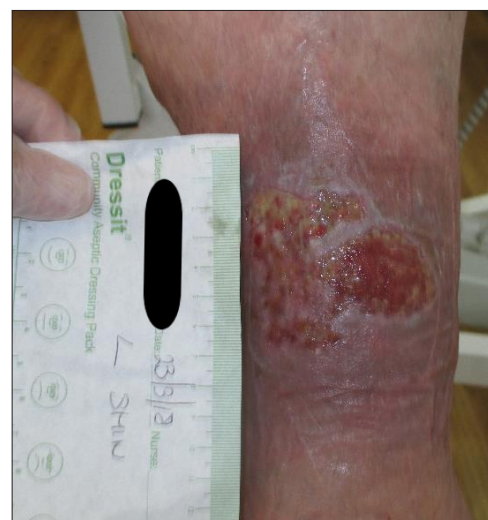
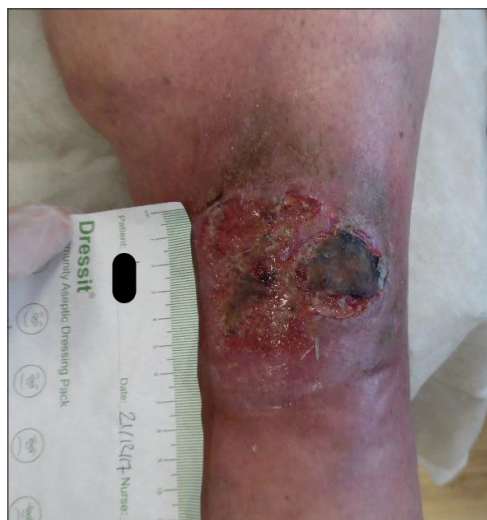
Figure 10 (left). Case study 3: The wound at initial presentation.

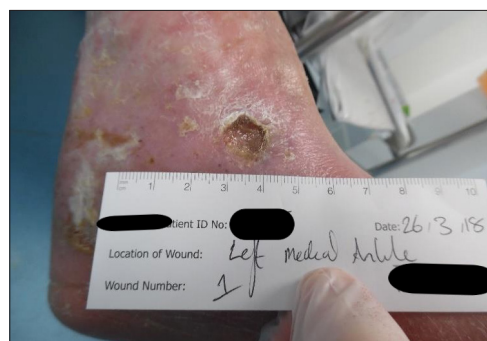
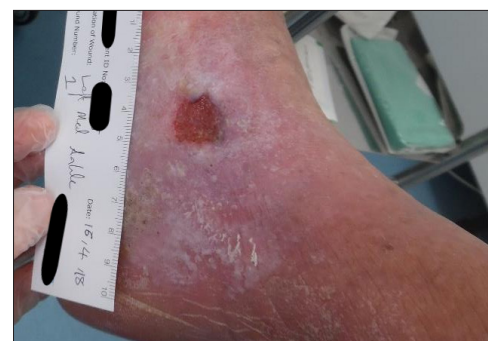
Figure 11 (right). Case study 3: The wound following 3 weeks of treatment with easywrap.



Case study 3

Case study 3 records a patient whose wound had previously healed in bandages and chose to maintain in wrap garments, however, he had a recurrence of his ulcer due to suspected trauma on the dorsum of his left foot. During his first course of treatment he had some challenges regarding compression due to anxiety and some compulsive behavioural disorders, which delayed healing. When it came to garment provision, the ACWD garment was selected to give him some control and empower him to provide his own care.

On his return to the clinic with the new wound, the authors discussed his treatment options and agreed to utilise the ACWD he already had, as his compression therapy needed to facilitate the wound healing, rather than restart the bandaging. He finds this very comfortable and does not cause him anxiety as he is getting used to the garments. *Figures 10 and 11* show the wound at initial presentation and after 3 weeks of treatment — note the periwound area in *Figure 11* is mildly macerated following a 15-minute PHMB soak as part of the care plan. While the wound measurements have remained fairly stable, all the slough and devitalised tissue has been removed and the wound bed is now granulating, is level with

surrounding tissues and has begun to contract, reducing by 0.2 cm on the right hand side where new epithelial tissue has started to form and should continue to progress.

Conclusion

The treatment of wounds has a huge impact on resources within the NHS and quality of life for patients. The case studies within this article demonstrate that using ACWD as an alternative to traditional bandaging techniques has improved outcomes of treatment and wound healing over an 18-week period. This, in turn, has reduced the burden of wound care and bandaging on the local clinic, allowing for reallocation of resources and a reduction in spend on compression bandaging systems. It is important for clinicians involved in the management of leg ulcers to consider novel and alternative, evidence-based approaches are considered to make a positive impact on leg ulcer treatment, which enables patient inclusion and promotes self-management in leg ulcer management. **WINT**

Declaration

Permission from a UK-based clinic was granted to reproduce the case studies in this article, while remaining anonymous.

References

- Damstra RJ, Partsch H (2013) Prospective, randomised, controlled trial comparing the effectiveness of adjustable compression velcro wraps versus inelastic multicomponent compression bandages in the initial treatment of leg lymphoedema. *J Vasc Surg Venous Lymphat Disord* 1(1): 13–9
- Elwell R (2015) Compression bandaging for chronic oedema: applying science to reality. *Br J Community Nurs* 20(5 Suppl): S4–S7
- Lee N (2017) *A Comparative Evaluation to Determine the Compression Levels and Static Stiffness Index Achieved in Four Velcro Wrapping Compression Devices*. Poster Presentation at: International Lymphoedema Framework Conference; Siracusa, Italy. June 21–24, 2017.
- Lee N, Lawrence S (2017) Haddenham easywrap: the latest innovation in the management of lymphoedema. *Br J Community Nurs* 22 Suppl 5(Sup5): S14–S21
- Lymphoedema Framework (2006) *Best Practice for the Management of Lymphoedema. International Consensus*. MEP Ltd, London
- Moffatt C (2007) *Compression Therapy in Practice*. Wounds UK Publishing, Trowbridge
- Moffatt CJ, Keeley V, Franks PJ et al (2016) Chronic oedema: a prevalent health care problem for UK health services. *Int Wound J* 14(5) 772–81
- Nazarko L (2017) Simplifying the management of venous leg ulcers: Choosing appropriate and acceptable compression therapy. *Br J Community Nurs* 22(Sup6): S6–S12
- Partsch H (2005) The static stiffness index: a simple method to assess the elastic property of compression material in vivo. *Dermatol Surg* 31(6): 625–30
- Ritchie G (2017) Chronic leg ulcers. *Nurse Prescribing* 15(9): 430–1
- Scottish Intercollegiate Guidelines Network (2010) *Management of Chronic Venous Leg Ulcers SIGN 120*. SIGN, Edinburgh
- Todd M (2011) Venous leg ulcers and the impact of compression bandaging. *Br J Nurs* 20(21): 1360–4
- Wigg J, Lee N (2014) Redefining essential care in lymphoedema. *Br J Community Nurs* 19(4): S20–S27
- Williams A (2017) An updated review of the evidence for adjustable compression wrap devices in the lower limb. *Nurse Prescribing* 15(Sup10): 6–13
- Woodcock TE, Woodcock TM (2012) Revised Starling equation and the glycocalyx model of transvascular fluid exchange: an improved paradigm for prescribing intravenous fluid therapy. *Br J Anaesthesia* 108(3): 384–94
- Wounds UK (2015) *Making the Case. FarrowWrap*. Available at: <https://bit.ly/2RQZwvr> (accessed 13.11.2018)